

OS TRIGONUM SYNDROME

Incidence:

- 10% unilateral and 2% bilateral in general population¹.
- Bilateral occurs in 50% of os trigonum population⁴.

Mechanism of Injury:

- Os trigonum syndrome occurs due to repetitive, forceful plantarflexion (or pointing). This commonly affects dancers, especially those assuming the extreme plantarflexed position that pointe work requires.
- Athletes may also experience os trigonum syndrome due to pushoff maneuvers (i.e. kicking, downhill running, and jumping).

What is it:

- Os trigonum results from a secondary ossification center, thought to develop between 7-13 years old. Usually, the ossicle fuses to the talus, forming the posterolateral process of the talus or Steida's process. However, the os trigonum is present when nonunion occurs.
- When a dancer attempts to forcefully point the foot beyond its range, the os trigonum is caught between the posterior lip of the tibia and the os calcis which may result in a fracture of the posterolateral process.
- There are 4 categories for the anatomical position of the posterolateral talus:
 - I. Normal posterolateral talar process
 - II. Elongated posterolateral talar process, or Steida's process
 - III. Accessory bone or os trigonum
 - IV. Os trigonum fused with posterolateral talus by cartilage or ligament (via synchondrosis or syndesmosis)

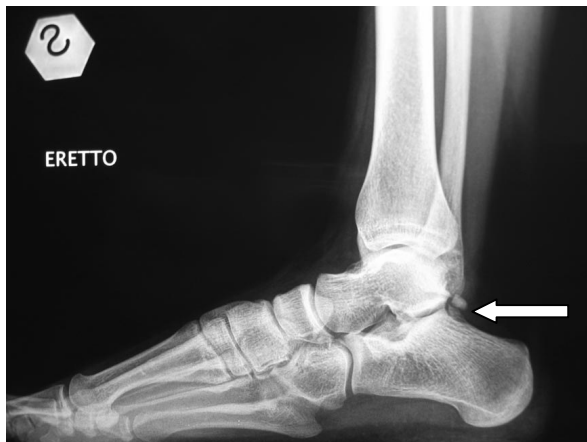

Figure 1: Note the presence of os trigonum.

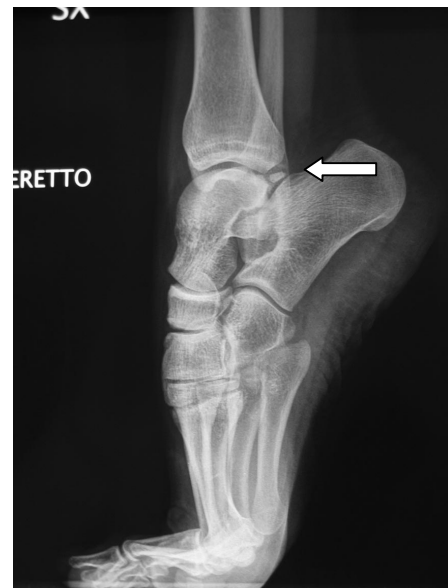

Figure 2: Note the posterior impingement of os trigonum during releve.

Symptoms:

- Pain on the outside of ankle, between Achilles and the lateral ankle bone (lateral malleolus of fibula)
- Pain with tendus, releves, and pointe work
- Swelling in ankle and/or foot
- Tenderness on outside of ankle
- Increased pain with forced pointing (plantarflexion) and wearing high heels
- May have concurrent symptoms of posterior ankle pain radiating into the medial arch due to flexor hallucis longus tenosynovitis (*see FHL tenosynovitis*)
- May be asymptomatic

Clinical Presentation:

- Pain with forced passive plantarflexion; pain with palpation in posterolateral ankle region, swelling in ankle and hindfoot, decreased ankle plantarflexion range of motion, presence of bony prominence in posterior ankle joint, decreased talo-crural joint motion, lateral position of os trigonum will force varus position that may cause lateral ankle sprains (*see lateral ankle sprains*), and majority of plantarflexion occurs from midfoot region.

Risk factors/Sequelae:

- Structural/ anatomic:
 - Presence of os trigonum or large Steida's process
 - Previous ankle sprains decrease control and stability of ankle joint, such that the talus is not held in proper position.
- Dance choreography: repetitive pointing, relevés, and pointe work
- Sport activity: repetitive kicking for soccer, pushoff for swimming, jumping, and running downhill.
- Decreased midfoot mobility, causing forced plantarflexion solely from talocrural joint

Treatment:

There are three main goals for treatment of os trigonum. 1) Reducing swelling, 2) strengthening foot and ankle musculature, and 3) mobilization of the ankle joint. Initially, conservative management aims at reducing swelling and decreasing pain. This involves applying ice to the ankle with compression 2-4 times per day, for 10-20 minutes each. NSAIDs are also helpful to reduce inflammation and provide pain relief. With os trigonum syndrome, modification of activities is the most important aspect of rehabilitation. Because repetitive plantarflexion exacerbates symptoms, healing cannot occur unless this motion is limited. Patients are instructed to modify their dance movements, working only in painfree ranges and eliminating relevés and pointe work. Strengthening of the foot intrinsics and ankle stabilizers provides support for the ankle, allowing improved joint position and decreased stress on the joint. Mobilization is also important to restore proper joint mechanics, in order to improve plantarflexion mobility and avoid pinching of the posterolateral process within the ankle joint.

At PAPT, rehabilitation initially focuses on reducing swelling and decreasing pain through manual therapy and modalities. Edema mobilization, icing, ultrasound, and electrical stimulation control the inflammatory process and provide an optimal environment for healing to occur. Next, therapeutic exercises and neuromuscular reeducation focus on restoring plantarflexion range of motion, strengthening foot and ankle musculature, and improving motor control and proprioception. By inhibiting overuse of the calf muscles during pointe and using the ankle stabilizers instead, this will delay the impact of the os trigonum on the posterior tibia. Mobilization of both the midfoot and ankle joint is extremely important to increase available range of motion and prevent the dancer from aggressively forcing plantarflexion and exacerbating symptoms. Patients are encouraged to actively participate in their rehabilitation program, through regular icing to decrease swelling, modifying activities to allow healing to occur, and compliance with their home exercise program.

Modalities	Manual Therapy	Therapeutic Exercise	Neuro Re-ed
<ul style="list-style-type: none"> • Phonophoresis • Cryotherapy • Electrical Stimulation 	<ul style="list-style-type: none"> • Edema mobilization • Joint mobilization (midfoot/ankle) • Soft tissue mobilization • Trigger point release 	<ul style="list-style-type: none"> • Intrinsic Strengthening: <ul style="list-style-type: none"> ○ Doming ○ Towel scrunches ○ Marble pick-ups • Foam roller • Weight shift relevés • Theraband relevés • 2 to 1 eccentric relevés • Theraband ankle exercises • Calf stretches • Plyometrics to return to dance <ul style="list-style-type: none"> ○ 2 footed sautes, all planes ○ 1 footed sautes and jetés, all planes 	<ul style="list-style-type: none"> • Skeletal Alignment Exercise • Gait Training • BAPS board • Pilates Reformer footwork • Pilates leg springs series (for proximal control) • Pilates jump board • Static balance activities: <ul style="list-style-type: none"> ○ On compliant surfaces such as Dyna Disc, slant board, pillow, etc. ○ Progression to single limb, with reaching, on relevé, and other external perturbations

1. Hamilton, W.G., *Stenosing tenosynovitis of the flexor hallucis longus tendon and posterior impingement upon the os trigonum in ballet dancers*. Foot Ankle, 1982. **3**(2): p. 74-80.
2. Howse, A.J., *Posterior block of the ankle joint in dancers*. Foot Ankle, 1982. **3**(2): p. 81-4.
3. Marotta, J.J. and L.J. Micheli, *Os trigonum impingement in dancers*. Am J Sports Med, 1992. **20**(5): p. 533-6.
4. Rathur, S., P.D. Clifford, and C.B. Chapman, *Posterior ankle impingement: os trigonum syndrome*. Am J Orthop, 2009. **38**(5): p. 252-3.
5. Uzel, M., et al., *Bilateral os trigonum syndrome associated with bilateral tenosynovitis of the flexor hallucis longus muscle*. Foot Ankle Int, 2005. **26**(10): p. 894-8.
6. Wredmark, T., et al., *Os trigonum syndrome: a clinical entity in ballet dancers*. Foot Ankle, 1991. **11**(6): p. 404-6.

POSTERIOR ANKLE IMPINGEMENT SYNDROME (PAIS)

Mechanism of Injury:

- 10% unilateral and 2% bilateral os trigonum in general population⁵; Bilateral occurs in 50% of os trigonum population¹⁰.

What is it?:

- PAIS syndrome is pain in the posterior aspect of ankle, due to repetitive, forceful plantarflexion (or pointing). This commonly affects dancers, especially those assuming the extreme plantarflexed position that pointe work requires.
- Athletes may also experience PAIS due to pushoff maneuvers (i.e. kicking, downhill running, and jumping).

Symptoms:

- Pain on the outside of ankle, between Achilles and the lateral ankle bone (lateral malleolus of fibula)
- Pain with tendus, relevés, and pointe work
- Swelling in ankle and/or foot
- Tenderness on outside of ankle
- Increased pain with forced pointing (plantarflexion) and wearing high heels
- May have concurrent symptoms of posterior ankle pain radiating into the medial arch due to flexor hallucis longus tenosynovitis (*see FHL tenosynovitis*)
- May be asymptomatic

Clinical Presentation:

- Pain with forced passive plantarflexion; pain with palpation in posterolateral ankle region, swelling in ankle and hindfoot, decreased ankle plantarflexion range of motion, presence of bony prominence in posterior ankle joint, decreased talo-crural joint motion, lateral position of os trigonum will force varus position that may cause lateral ankle sprains (*see lateral ankle sprains*), and majority of plantarflexion occurs from midfoot region.

Risk factors/Sequelae:

- Structural/ anatomic:
 - **Figure 1** illustrates the bony abnormalities that contribute to PAIS. 1) the Steida process is a lengthened posterior tubercle of the talus, 2) os trigonum (*see os trigonum syndrome*), 3) fractured tubercle of talus due to trauma via forced plantarflexion, 4) downward slope of posterior tibia, 5) calcified loose bodies from previous ligamentous injury, and 5) Haglund's deformity, a bony protuberance due to repetitive friction from shoes.

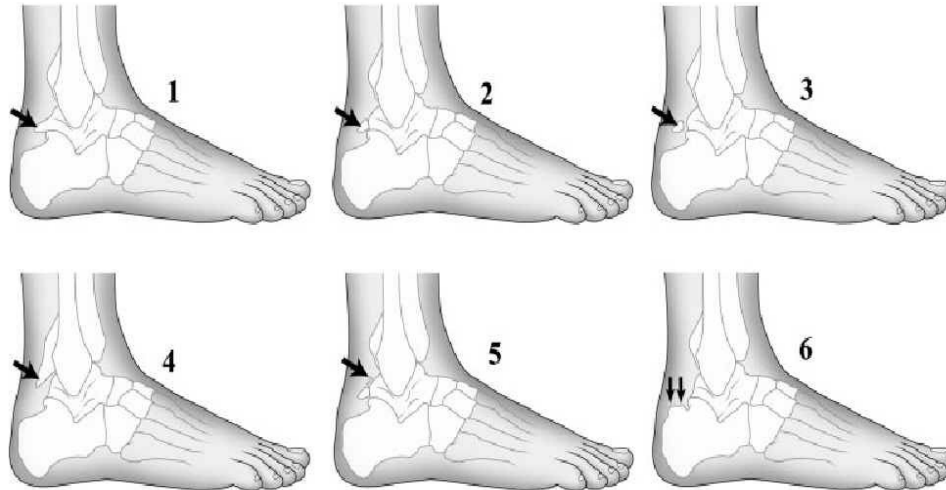


Figure 1 Line drawing demonstrating variations in posterior ankle anatomy that contribute to posterior ankle impingement syndrome. The top row demonstrates variations in the lateral tubercle of the posterior process of the talus: 1, Stieda process; 2, os trigonum; 3, fractured lateral tubercle of talus. The bottom row illustrates the other osseous abnormalities implicated in the etiology of posterior ankle impingement syndromes: 4, downward sloping posterior tibial plafond; 5, calcified loose bodies; 6, Haglund's deformity.

- During plantarflexion (pointing), the posterior talar process or the os trigonum are compressed between the tibia and the calcaneus.
- Compression of the posterior soft tissue structures (i.e. flexor hallucis longus tendon, and posterior capsule of ankle joints) causes the presentation of symptoms. This also may result in thickened, calcified inflammatory tissues.

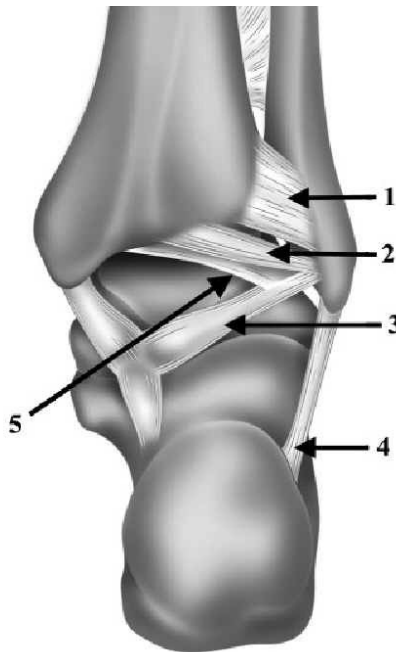


Figure 5 Line drawing of posterior ankle ligaments. Note 1, posterior inferior tibiofibular ligament; 2, intermalleolar ligament; 3, posterior talofibular ligament; 4, calcaneofibular ligament; and 5, the tibial slip.

- **Figure 5** shows the posterior ankle ligaments that are affected by PAIS. The intermalleolar ligament (2), when thickened, is considered the labrum of the ankle and causes pain when compressed within the joint. Lesions of the posterior inferior tibiofibular ligament (1) and the tibial slip (5) may also accompany PAIS.
- Technique:

- To prevent compression of posterior soft tissue structures, dancers may assume an inverted (sickled) positioning that predisposes them to lateral ankle sprains (*see lateral ankle sprains*).
- Dance choreography: repetitive pointing, relevés, and pointe work
- Sport activity: repetitive kicking for soccer, pushoff for swimming, jumping, and running downhill.
- Decreased midfoot mobility, causing forced plantarflexion solely from talocrural joint

Treatment:

There are three main goals for treatment of os trigonum. 1) Reducing swelling, 2) strengthening foot and ankle musculature, and 3) mobilization of the ankle joint. Initially, conservative management aims at reducing swelling and decreasing pain. This involves applying ice to the ankle with compression 2-4 times per day, for 10-20 minutes each. NSAIDs are also helpful to reduce inflammation and provide pain relief. With os trigonum syndrome, modification of activities is the most important aspect of rehabilitation. Because repetitive plantarflexion exacerbates symptoms, healing cannot occur unless this motion is limited. Patients are instructed to modify their dance movements, working only in painfree ranges and eliminating relevés and pointe work. Strengthening of the foot intrinsics and ankle stabilizers provides support for the ankle, allowing improved joint position and decreased stress on the joint. Mobilization is also important to restore proper joint mechanics, in order to improve plantarflexion mobility and avoid pinching of the posteriolateral process within the ankle joint.

At PAPT, rehabilitation initially focuses on reducing swelling and decreasing pain through manual therapy and modalities. Edema mobilization, icing, ultrasound, and electrical stimulation control the inflammatory process and provide an optimal environment for healing to occur. Next, therapeutic exercises and neuromuscular reeducation focus on restoring plantarflexion range of motion, strengthening foot and ankle musculature, and improving motor control and proprioception. By inhibiting overuse of the calf muscles during pointe and using the ankle stabilizers instead, this will delay the impact of the os trigonum on the posterior tibia. Mobilization of both the midfoot and ankle joint is extremely important to increase available range of motion and prevent the dancer from aggressively forcing plantarflexion and exacerbating symptoms. Patients are encouraged to actively participate in their rehabilitation program, through regular icing to decrease swelling, modifying activities to allow healing to occur, and compliance with their home exercise program.

Modalities	Manual Therapy	Therapeutic Exercise	Neuro Re-ed
<ul style="list-style-type: none"> • Phonophoresis • Cryotherapy • Electrical Stimulation 	<ul style="list-style-type: none"> • Edema mobilization • Joint mobilization (midfoot/ankle) • Soft tissue mobilization • Trigger point release 	<ul style="list-style-type: none"> • Intrinsic Strengthening: <ul style="list-style-type: none"> ○ Doming ○ Towel scrunches ○ Marble pick-ups • Foam roller • Weight shift relevés • Theraband relevés • 2 to 1 eccentric relevés • Theraband ankle exercises • Calf stretches • Plyometrics to return to dance <ul style="list-style-type: none"> ○ 2 footed sautes, all planes ○ 1 footed sautes and jetes, all planes 	<ul style="list-style-type: none"> • Skeletal Alignment Exercise • Gait Training • BAPS board • Pilates Reformer footwork • Pilates leg springs series (for proximal control) • Pilates jump board • Static balance activities: <ul style="list-style-type: none"> ○ On compliant surfaces such as Dyna Disc, slant board, pillow, etc. ○ Progression to single limb, with reaching, on releve, and other external perturbations

1. Albisetti, W., et al., *Clinical evaluation and treatment of posterior impingement in dancers*. Am J Phys Med Rehabil, 2009. **88**(5): p. 349-54.
2. Brodsky, A.E. and M.A. Khalil, *Talar compression syndrome*. Foot Ankle, 1987. **7**(6): p. 338-44.
3. Hamilton, W.G., M.J. Geppert, and F.M. Thompson, *Pain in the posterior aspect of the ankle in dancers. Differential diagnosis and operative treatment*. J Bone Joint Surg Am, 1996. **78**(10): p. 1491-500.
4. Hamilton, W.G., *Foot and ankle injuries in dancers*. Clin Sports Med, 1988. **7**(1): p. 143-73.

5. Hamilton, W.G., *Stenosing tenosynovitis of the flexor hallucis longus tendon and posterior impingement upon the os trigonum in ballet dancers*. *Foot Ankle*, 1982. **3**(2): p. 74-80.
6. Hardaker, W.T., Jr., S. Margello, and J.L. Goldner, *Foot and ankle injuries in theatrical dancers*. *Foot Ankle*, 1985. **6**(2): p. 59-69.
7. Lee, J.C., J.D. Calder, and J.C. Healy, *Posterior impingement syndromes of the ankle*. *Semin Musculoskelet Radiol*, 2008. **12**(2): p. 154-69.
8. Maquirriain, J., *Posterior ankle impingement syndrome*. *J Am Acad Orthop Surg*, 2005. **13**(6): p. 365-71.
9. Peace, K.A., et al., *MRI features of posterior ankle impingement syndrome in ballet dancers: a review of 25 cases*. *Clin Radiol*, 2004. **59**(11): p. 1025-33.
10. Rathur, S., P.D. Clifford, and C.B. Chapman, *Posterior ankle impingement: os trigonum syndrome*. *Am J Orthop*, 2009. **38**(5): p. 252-3.